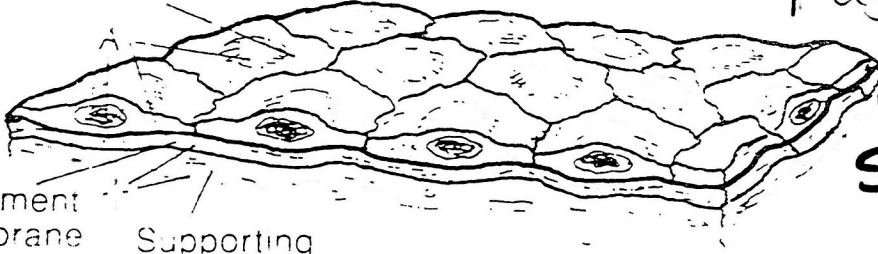


Coloring Book Exercise 1.1

Follow instructions in your coloring book -

Page 10
(In Coloring Book)

Free surface

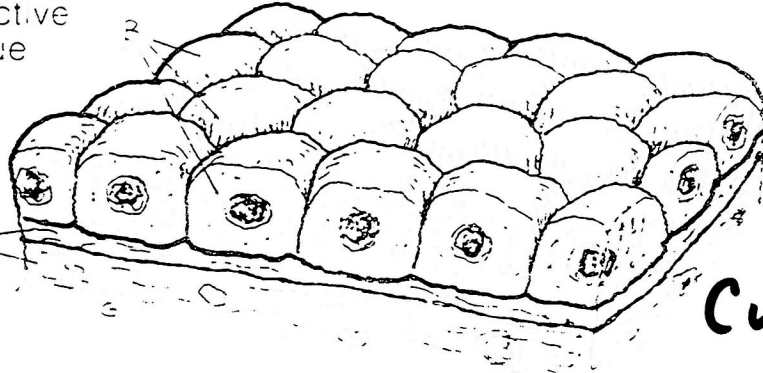


Squamous

Basement membrane


Supporting connective tissue

SIMPLE

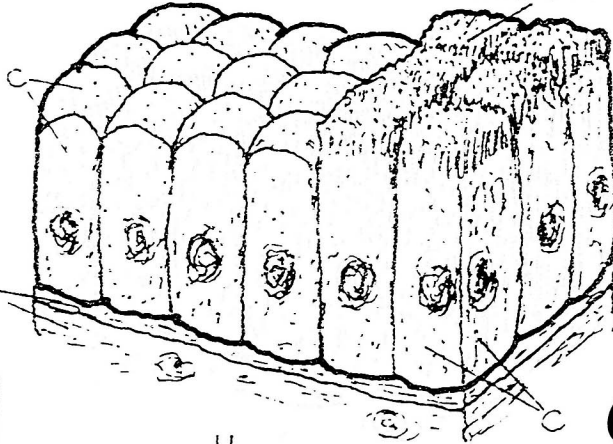


Cuboidal

Blood vessel

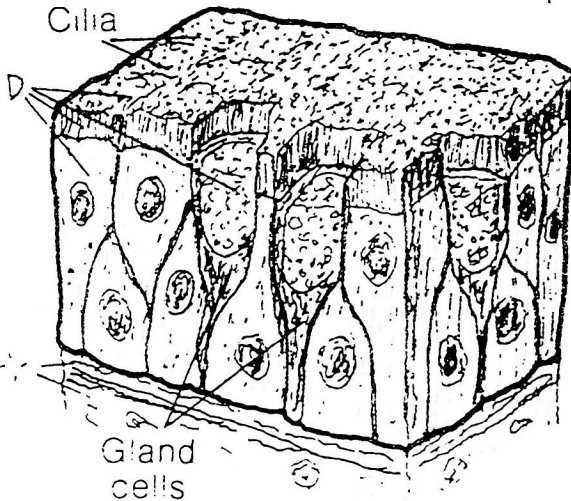


Microvilli

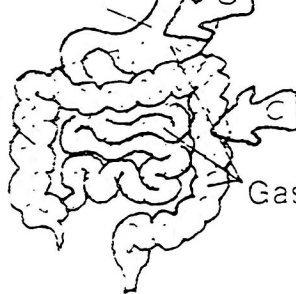


Columnar

Cilia



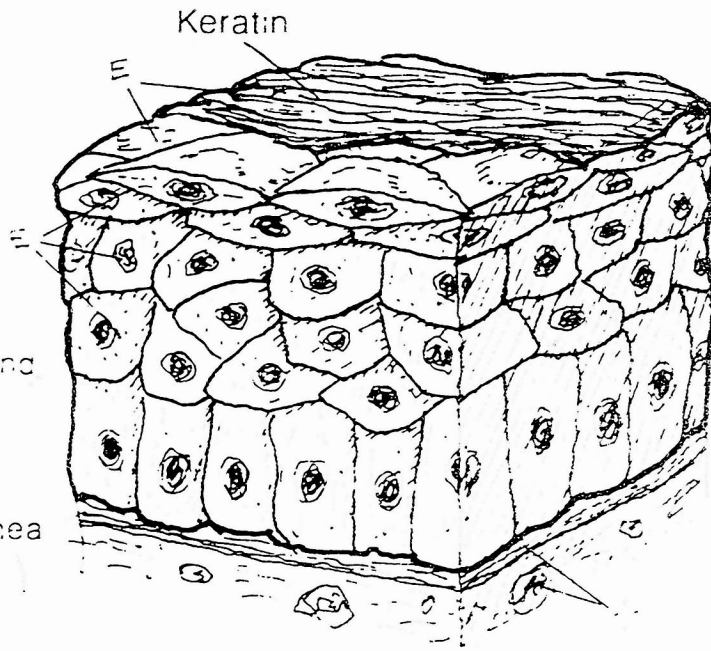
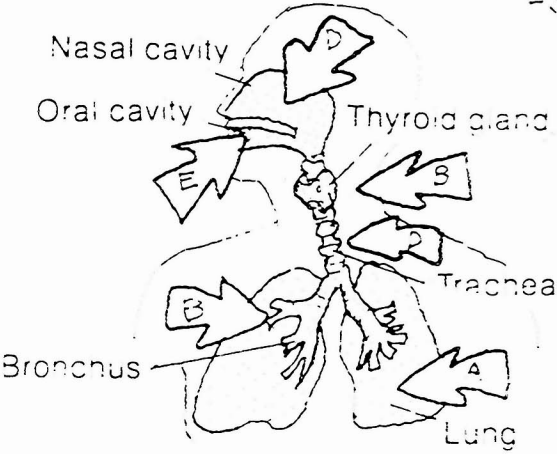
Stomach



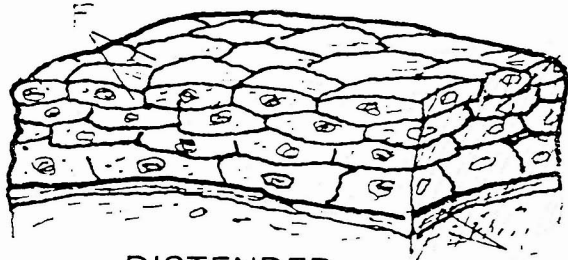
Gastrointestinal tract

Pseudostratified Columnar

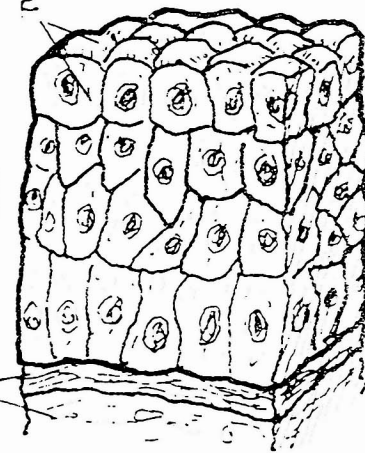
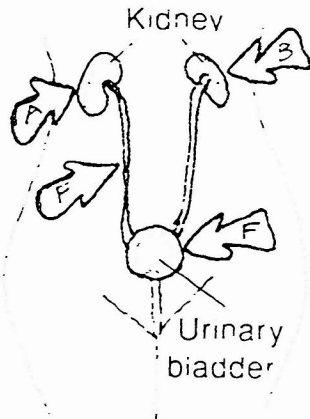
STRATIFIED



Squamous

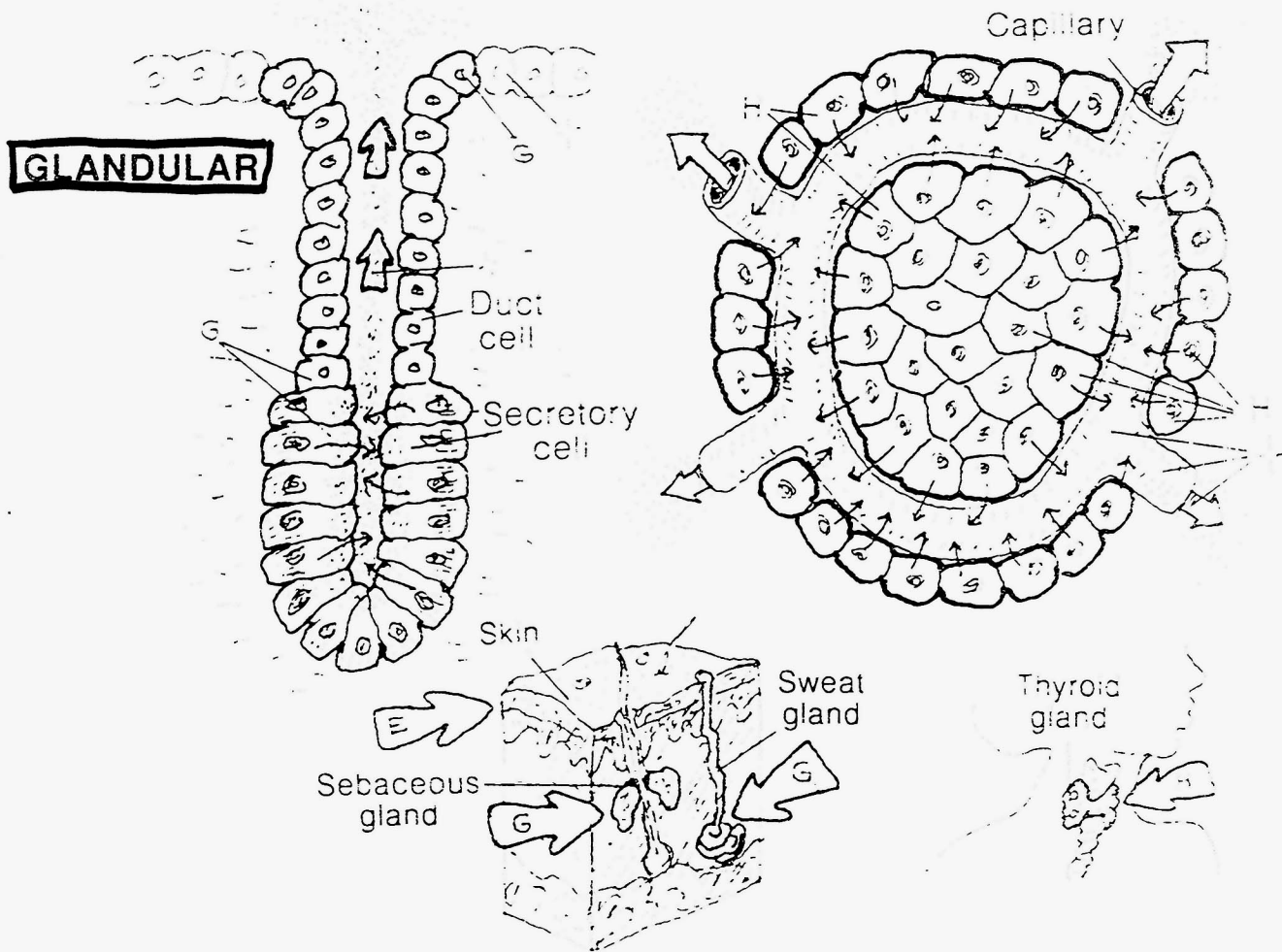


DISTENDED
(Tissue stretched)



CONTRACTED
(Tissue not stretched)

Transitional



Exocrine (G)

Endocrine (H)